



**PATIENT**

Sir Butterscotch  
Drummond

**SPECIES**

Feline

**BREED**

Himalayan

**SEX**

Male Neutered

**AGE**

6 years

**WEIGHT**

9lbs

**INTERPRETED BY**

Maggie Machen Lamy,  
DVM, DACVIM  
(Cardiology)

**IMAGING PERFORMED BY**

Dr. Karen Ebersole

**HOSPITAL NAME**

Scanvet

**REFERRING VET**

Dr. Drummond

**INVOICE**

28292

**DATE**

1/14/23

**PRESENTING CLINICAL SIGNS**

History: Recent acute onset vomiting and diarrhea. Vomiting has resolved but still not eating. Acting normally. No heart murmur. Heart possibly enlarged on X-ray, Sedated with Torb.  
-Abnormal PE/Chem/CBC/UA Results: CBC/Chem/T-4: all WNL

**ECHOCARDIOGRAM FINDINGS**

2D, m-mode, color flow and doppler imaging is available. The left ventricular wall is normal in dimension with a largely normal appearance. No obvious LVH. Mild LV dilation with adequate myocardial function. There is a mildly hyperechoic endocardium consistent with fibrosis. The endocardium also appears mildly remodeled. Remodeled hyperechoic papillary muscles. The left atrium is severely dilated. Subtle smoke. The right atrium is normal. Trace TR. The right ventricle appears normal. The mitral valve is normal in structure and mobility. Trace central MR. Blood flow through both the LVOT and RVOT are normal in velocity. No PI or AI. No effusions or obvious cardiac tumors identified.

**CARDIAC CHART**

FELINE CARDIAC PARAMETERS	BODY WEIGHT (kg)	HR (BPM)	IVSd (cm) (Moise, Pipers)	LVIDd (cm) (Moise, Pipers)	LWVd (cm) (Moise, Pipers)	FS (%)	EF (%)
NORMAL PARAMETER	-----	150-240	0.35-0.55	<2 (mean 1.5)	3.5-0.55	35-67	80-100
PATIENT	4.1	NM	0.45	1.72	0.46	50	94
FELINE CARDIAC PARAMETERS	LA/AO (Boon)	LA/AO HEART BASE (Swe) (Abbott)	LA 2D short axis Base view (cm) (Abbott)		LVOT VEL (m/s)	RVOT VEL (m/s)	E max (m/s)
NORMAL	<1.5	<1.3	<1.2		<1.6	<1.3	<0.9
PATIENT	2.0	2.3	1.9		0.94	1.5	NM

*\*Note: All measurements based upon multi-modal images and methods. An average value is reported.  
Adapted from June Boon, Veterinary Echocardiography, 1998  
Abbott J & MacLean H JVIM 2006;20: 111-119, Moise et al. Am J Vet Res 47:1476, 1986. Pipers et al. Am J Vet Res 40:882, 1979.*

**INTERPRETATION OF THE FINDINGS & FURTHER RECOMMENDATIONS**

The LV wall dimension are normal in this patient, with no overt evidence of HCM. There is however severe LA enlargement, which is concerning for progressive disease. The academic diagnosis could be argued in this case, with unclassified cardiomyopathy most likely. Regardless, severe left atrial enlargement with evidence of subtle smoke indicates the risk for complication is high. No additional issues are identified.

It is important to note that no medications have been shown to change the course of disease at this stage. That being said, due to LA dilation I would consider institution of Pimobendan and Plavix at this juncture. An ACE-I could also be argued; however, baseline blood pressure assessment should be performed first. No obvious indication for Lasix or additional medications at this time; however, close monitoring is advised.

Elective anesthesia, fluid or steroid therapy is not advised.



**PATIENT**

Sir Butterscotch  
Drummond

Monitor for any development of clinical signs at home, including labored breathing, cough, or signs of a blood clot (paralysis, neurologic change). Monitoring of sleeping breathing rates is recommended to screen for early decompensation going forward. Patient will always be at risk for spontaneous CHF, development of blood clots and/or sudden death in the future. Prognosis is guarded to poor long-term given the degree of disease seen here

**SPECIES**

Feline

**PLAN**

Institute Plavix 18.75mg PO q24h (NOTE: Medication is bitter along the cut edge; coat in entirety or place in a gel cap). Institute Pimobendan 1.25mg PO q12h. Baseline BP is recommended. If >150mmHg, institute ACEI 0.5mg/kg PO q12h.

**BREED**

Himalayan

A recheck echocardiogram is recommended in 6 months to screen for progressive atrial dilation, sooner if clinical issues arise in the interim.

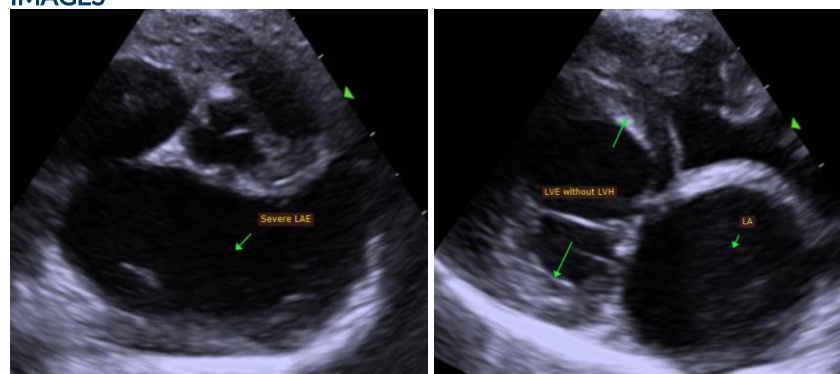
**SEX**

Male Neutered

**IMAGES**

**AGE**

6 years



**WEIGHT**

9lbs

The information and recommendations provided are based on the images presented by the referring veterinarian. No evaluation can be communicated regarding pathology that was not visible in the image/video clips provided.

**INTERPRETED BY**

Maggie Machen Lamy,  
DVM, DACVIM  
(Cardiology)

Thank you for this referral. This report was generated using transcription software, and minor dictation errors may be present. If the clinical or image interpretation does not parallel your findings or if I can be of any further assistance, please contact me.

**IMAGING PERFORMED BY**

Dr. Karen Ebersole

**HOSPITAL NAME**

Scanvet

Maggie Machen Lamy, DVM  
Diplomate of the American College of Veterinary Internal Medicine (Cardiology)  
info@sonopath.com

**REFERRING VET**

Dr. Drummond

**INVOICE**

28292

**DATE**

1/142/23



**PATIENT**

Sir Butterscotch  
Drummond

**SPECIES**

Feline

**BREED**

Himalayan

**SEX**

Male Neutered

**AGE**

6 years

**WEIGHT**

9lbs

**INTERPRETED BY**

Maggie Machen Lamy,  
DVM, DACVIM  
(Cardiology)

**IMAGING  
PERFORMED BY**

Dr. Karen Ebersole

**HOSPITAL NAME**

Scanvet

**REFERRING VET**

Dr. Drummond

**INVOICE**

28292

**DATE**

1/14/23